



Endoparasites of rabbits (*Oryctolagus cuniculus domesticus*) in Southern Ukraine

M. V. Bogach*, A. P. Paliy*, O. O. Horobei*, L. V. Perotska**, V. Y. Kushnir**, D. M. Bohach***

*Institute of Experimental and Clinical Veterinary Medicine, Kharkiv, Ukraine

**Odesa State Agrarian University, Odesa, Ukraine

***Odesa Research Station of the Institute of Experimental and Clinical Veterinary Medicine, Odesa, Ukraine

Article info

Received 01.05.2022

Received in revised form
29.05.2022

Accepted 31.05.2022

Institute of Experimental and
Clinical Veterinary Medicine,
Pushkinska st., 83,
Kharkiv, 61023, Ukraine.
Tel.: +38-067-997-49-25.
E-mail: bogach_mv@ukr.net

Odesa State Agrarian University,
Panteleymonovska st., 13,
Odesa, 65000, Ukraine.
Tel.: +38-067-785-61-94.
E-mail: perotskaya@ukr.net

Odesa Research Station of the
Institute of Experimental and
Clinical Veterinary Medicine,
Svobody av., 2, Odesa,
65037, Ukraine. Tel.: +38-093-
823-93-38. E-mail:
bogachdenis1@gmail.com

Bogach, M. V., Paliy, A. P., Horobei, O. O., Perotska, L. V., Kushnir V. Y., & Bohach, D. M. (2022). Endoparasites of rabbits (*Oryctolagus cuniculus domesticus*) in Southern Ukraine. *Biosystems Diversity*, 30(2), 173–178. doi:10.15421/012218

One of the main tasks of ecological parasitology at the present stage is to establish patterns of spread of invasive diseases of animals in the environment through a thorough epidemiological examination, as well as to determine the main directions and factors of spread of parasites in Ukraine. Among the many pathogens, endoparasites play a major role in a number of diseases in rabbits with increased morbidity and mortality. In the body of both wild and domestic rabbits several species of parasites that form a parasitocenosis can be localized. The latter have a pathogenic effect on organs and tissues, leading to reduced weight gain, premature slaughter and even mortality. The prevalence of endoparasitoses was studied in weaned rabbits 60 days of age, 120 days of age at fattening, 180 days of age – mating age and adults of 320 days of age to determine the extensiveness and intensity of the dominant invasion. A total of 720 head was studied, 180 animals from each age group. Three species of nematodes were recorded in the rabbits: *Trichostrongylus retortaeformis* (Zeder, 1800), *Nematodirus leporis* (Ransom, 1907) and *Passalurus ambiguus* (Rudolphi, 1819); the cestode *Taenia pisiformis* (Bloch, 1780); three species of Eimeria: *Eimeria stiedae* (Lindermann, 1865), which parasitizes in the bile ducts of the liver and gallbladder, *E. magna* (Perard, 1925) and *E. media* (Kessel, 1929) – in the epithelial cells of the intestine. The prevalence of the infestation depends on the age of the animals. According to the data obtained, eimeriosis was one of the main parasitic diseases of the rabbits. Dominant invasions of *Eimeria* in the intestines of 60-day-old rabbits were found in the studied animals, their extensiveness reached 19.4%, while the spread of hepatic *Eimeria* was registered in 13.3% of the examined rabbits. The total infestation of weaned rabbits with helminths was 22.2%, in rabbits for fattening – 26.7%, and in rabbits of mating age and adults – 20.0% and 20.6%, respectively. Global climate change will change the distribution and dynamics of soil-borne helminthiases, but host immunity may also affect host-parasite interactions. Subsequent studies will be aimed at elucidating the effect of mono and mixed invasions on the body of rabbits. Updated data on helminthiasis will expand the screening strategy to maintain rabbit health and reduce economic losses.

Keywords: *Trichostrongylus retortaeformis*; *Nematodirus leporis*; *Passalurus ambiguus*; *Taenia pisiformis*; *Eimeria* spp.

Introduction

One of the main tasks of ecological parasitology at the present stage is to establish patterns of spread of invasive pathogens in the environment through a thorough epidemiological examination, as well as to determine the main directions and factors of spread of parasites (Boyko & Brygadyrenko, 2019; Nakao et al., 2019; Boyko et al., 2021). Researchers believe that intestinal parasitoses is primarily a sanitary problem, and their prevention should be based on sanitary and parasitological monitoring (Ahmed et al., 2017). Parasitism is defined as an intimate relationship in which one partner is a parasite, lives on the host or in the host, usually at the expense of the latter. In most cases, parasitism leads to a unique series of physiological reactions and adaptation of the host. Most studies of the physiological aspects of parasitism focus on the pathological consequences of the invasion for the macroorganism. Although many physiological changes are characteristic of the pathogenesis of invasion, it is now recognized that parasitic diseases at subclinical levels also cause physiological effects that either improve or may not contribute to the development of the disease (Vaumourin et al., 2015).

Rabbit breeding is a promising industry, one of the most profitable in agriculture. A negative aspect of rabbit breeding is that they are very susceptible to many infectious (Laakkonen et al., 2006; Kosyanchuk, 2017) and invasive diseases (Li-Qun et al., 2020; Nasser et al., 2020). Among the many pathogens, parasites play a major role in the emergence of a number of diseases in rabbits with increased morbidity and mortality, leading to significant economic losses (Lans & Turner, 2011; Ola-Fadunsin et al., 2018). Some of the parasites are helminths, such as roundworms,

tapeworms and *Eimeria* (Szkucik et al., 2014; Hajipour & Zavarshani, 2020). A significant number of reports indicate that in the body of both wild and domestic rabbits several species of parasites that form parasitocenosis can be localized (Ola-Fadunsin et al., 2018; Hernandez et al., 2018; Pilarczyk et al., 2020). The latter have a pathogenic effect on organs and tissues, leading to reduced weight gain, premature slaughter and even mortality (Sharma et al., 2017).

In rabbits, a macroscopically white-spotted liver can be indicative of one of several disease processes that cause similar gross hepatic changes, consisting of small 1–2-mm, white-or-cream focal lesions scattered throughout the hepatic parenchyma. There are numerous parasitic causes of white-spotted livers in lagomorphs, including *E. stiedae*, *Taenia pisiformis*, which is the larval stage of *T. pisiformis*. The definitive hosts for this cestode are dogs and foxes, with rabbits an intermediate host. Tapeworm segments packed with eggs are shed in the feces of dogs and foxes, and the eggs are ingested from the pasture by rabbits. The larval stage migrates from the small intestine, and for a time in the liver, before encysting in the peritoneal cavity and sometimes in the liver. The life cycle is completed when an infected rabbit is eaten by the definitive host. The prevalence of *T. pisiformis* in a slaughter farmed rabbit population in Poland was estimated to be 4.47%, coccidia (78.83%), nematoda (16.42%), cestoda (0.72%), (Szkucik et al., 2014; Hrzenjak et al., 2021; Bochyńska et al., 2022).

Information on the prevalence of gastrointestinal parasites in rabbits in the south of Ukraine is limited and applies only to certain diseases (Duda et al., 2018; Bogach et al., 2020). Existing information contributes to a better understanding of the epidemiology of intestinal parasitic diseases

and can be used to develop science-based measures to combat and prevent invasion diseases.

The aim of the study was to determine the extensity and intensity of endoparasites of rabbits in farms in Southern Ukraine.

Materials and methods

The experiments performed on animals did not contradict the current legislation of Ukraine (Article 26 of the Law of Ukraine 5456-VI of 16.10.2012 “On protection of animals from cruel treatment”) and “General ethical principles of animal experiments”, adopted by the First National Congress of Bioethics (Kyiv, 2001) and international bioethical standards (materials of the IV European Convention for the Protection of Vertebrate Animals Used for Experimental and Other Purposes, Strasbourg, 1985) (Simmonds, 2018; Kabene & Baadel, 2019). The research program was reviewed and approved by the Bioethics Commission of the National Research Center “Institute of Experimental and Clinical Veterinary Medicine” in the current order.

The research was conducted on specialized rabbit farms of BBPROM LLC, p. Shemetove of Berezovsky district (165 rabbits were inspected), LLC Odessa-MIAKRO with p. Nerubaiske of Bilyaiv district (172 rabbits were inspected) and PSP “Druzhba” of Izmail district (115 rabbits were inspected) of Odessa region in which caged animals were used meeting all zoohygienic requirements with provision of a balanced diet (the main diet was granulated feed), as well as on private farms FG “Volyar” of Pervomaisky district of Mykolaiv region (193 rabbits were inspected) and FG “Smutko” of Belozirsky district of Kherson region (75 rabbits were inspected) in which the type of feeding was mixed (hay, grain and root crops were additionally added to the granulated fodder).

The diagnosis was established taking into account laboratory studies and postmortem autopsy data, carried out in the laboratory of parasitology of the Odessa Experimental Station of the National Scientific Center “Institute of Experimental and Clinical Veterinary Medicine” and the slaughterhouse during planned and forced slaughter of rabbits.

The prevalence of endoparasitoses was studied in weaned rabbits 60 days of age, 120 days of age at fattening, 180 days of age – mating age and adults of 320 days of age to determine the extensiveness and intensity of the dominant invasion. A total of 720 head was studied, 180 animals from each age group. Prior to the examination, the rabbits did not receive antiparasitic drugs. To detect eggs of helminths *Passalurus ambiguus*, *Nematodirus leporis* and *Trichostrongylus retortaeformis*, faecal samples

of rabbits were treated by standard parasitological methods of Fulleborn and Darling according to GOST 25383-82ST CMEA 2547-80. We used a biological light microscope “Biomed +” XSM-20 (“BioMed”, China) that serves as a guide for counting helminth eggs. After counting the helminth eggs, their number was multiplied by 15 and a number obtained that was taken as the number of eggs in 1 g of feces of the test animal. The intensity of helminth infection in animals was considered to be the average number of parasite eggs in 1 g of each animal’s feces according to the results of three studies.

Immediately after slaughter, the carcasses were carefully examined for protozoa and helminths. The small intestine of each rabbit was separated from the mesentery, cut longitudinally and immersed in phosphate-buffered saline (pH 7.2) for 10 minutes. The mucosa was scraped with a scalpel, after which both the intestinal contents and the mucosal scraping were washed with tap water through a sieve and examined both with the naked eye and under a microscope (8 × 10) (Soulsby, 1982; Bowman, 2020). Identification of parasites was performed on morphological grounds (Knopp et al., 2009; Dolbin et al., 2012; Jiménez et al., 2016).

The intensity of eimeriosis invasion was determined by counting the number of *Eimeria* oocysts in the microscopic specimen at low magnification (8 × 10). The oocysts in the faeces were counted according to a standardized combined method for determining their number in 1 g of faeces. *Eimeria* species identification was determined using biological characteristics such as oocyst size and morphology (curvature, presence or absence of oocyst residues, visible / invisible micropile, sporulation time) (Bowman, 2020). The level of spontaneous cysticercosis in rabbits was determined visually after slaughter and at autopsy by the number of specific blisters on the internal organs.

The datasets were expressed as mean (x) ± standard error of the mean (SE). Mathematical analysis of the study results was conducted in Statistica 13.3 IT Application (StatSoft Inc., USA). Differences between average values were considered statistically significant at P < 0.05 (ANOVA).

Results

Eimeria infestation of 60-day-old rabbits was 47.2%, 120-day-old rabbits – 18.9%, 180-day-old rabbits – 5.6% and 320-day-old rabbits – 1.7%, represented by three species: *E. stiedae* – parasitizes in the bile ducts of the liver and gallbladder, *E. magna* and *E. media* – in the epithelial cells of the intestine (Table 1).

Table 1
The spread of *Eimeria* in rabbits of different ages (Mean ± SE, n=180)

Pathogen	60 days of age		120 days of age		180 days of age		320 days of age	
	infected / prevalence, %	intensity, thousand oocysts in 1 g of feces	infected / prevalence, %	intensity, thousand oocysts in 1 g of feces	infected / prevalence, %	intensity, thousand oocysts in 1 g of feces	infected / prevalence, %	intensity, thousand oocysts in 1 g of feces
<i>Eimeria stiedae</i> (Lindermann, 1865)	24 / 13.3	3.21 ± 0.92	18 / 10.0	7.28 ± 4.49	1 / 0.6	4.36 ± 1.79	1 / 0.6	2.93 ± 3.17
<i>E. magna</i> (Perard, 1925)	35 / 19.4	8.56 ± 3.24	11 / 6.1	6.51 ± 2.21	7 / 3.9	3.72 ± 2.16	2 / 1.1	3.19 ± 1.84
<i>E. media</i> (Kessel, 1929)	26 / 14.4	6.31 ± 2.12	5 / 2.8	4.52 ± 3.44	2 / 1.1	2.81 ± 3.49	–	–

In rabbits aged 60 days, the intestinal form of eimeriosis was more often registered with an extent of 33.9%, while the hepatic form was registered in only 13.3% of rabbits. As the age of the rabbits increased, the extensiveness of invasion and intensity of the eimeriosis invasion decreased. In 120-day-old rabbits, there was a 2.5-fold reduction in eimeriosis lesions, but the hepatic form of *E. stiedae* was predominant, with a maximum invasion intensity of 7.28 ± 4.49 thousand oocysts in 1 g of feces. With a decrease in the infection of rabbits 180 days of age with *E. magna* (5 times), there were changes in the intensity of the invasion, which was manifested by a decrease of 2.3 times and the detection of carriers of *E. stiedae* and *E. media* with indicators from 2.81 ± 3.49 to 4.36 ± 1.79 thousand oocysts in 1 g of feces. In 320-day-old rabbits *E. media* was not registered, while *E. stiedae* and *E. media* were also carriers. Thus, with the age of rabbits, the degree of damage by eimeriosis decreases, which proves the formation of non-sterile immunity and reduces the infection of animals in the case of reinvasion and superinvasion.

Eimeria were detected in the bile ducts of the liver during the dissection of 60-day-old rabbits, and the intensity of the invasion was 3.21 ± 0.92 thousand oocysts per 1 g of feces. Despite the low intensity of the invasion, high mortality of suckling rabbits (15–49%) was noted, which indicates a significant pathogenicity of the pathogen *E. stiedae*. Such indicators indicate that the infection of young animals occurs in the first days of life – in contact with rabbit-parasitic carriers, which are the main source of eimeriosis.

In the intestinal form of eimeriosis, signs of inflammation of the iliac part of the small intestine, ulcers, hemorrhages and mucus were registered. The small and large intestines were overflowing with gases, their wall was pale, and the vessels of the mesentery were filled with blood (Fig. 1).

A small amount of yellowish-green semi-liquid mass with gas bubbles was observed in the intestinal cavity. Thick yellow-grey opaque mucus, speckled or more massive hemorrhages were found on the surface of the mucous membranes of the duodenum and intestines. Rounded wall

thickenings measuring 15 x 20 mm were visually visible in some areas of the hungry intestine.

In the hepatic form of eimeriosis, small speckled hemorrhages were observed in some parts of the liver, and whitish nodules of various sizes were observed on the surface of the organ (Fig. 2).

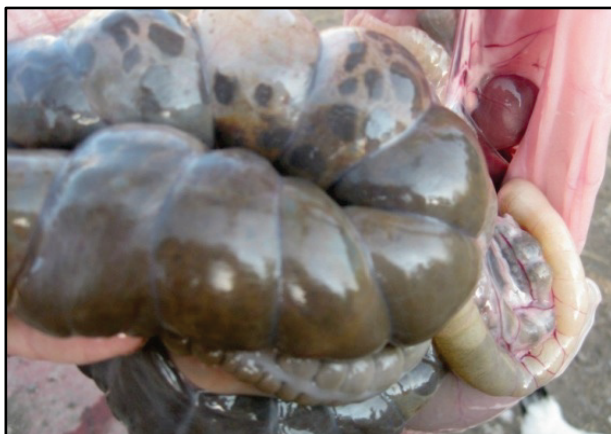

Fig. 1. Large bowel overflow of gases from *E. magna*

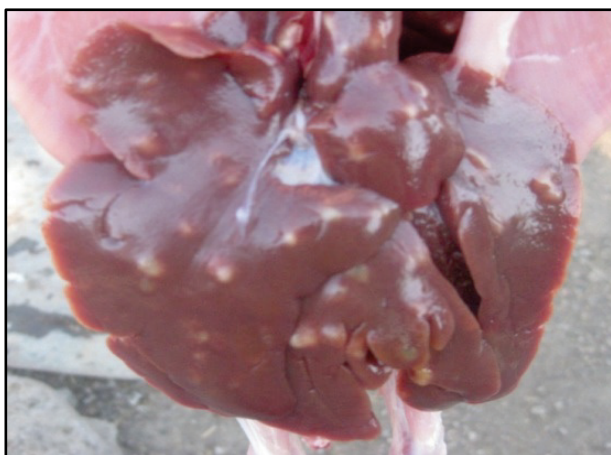

Fig. 2. Parasitic granulomas in rabbit liver with *E. stiedae*

The liver was enlarged, dark cherry colour, the capsule was moist, tense, unevenly hilly. The bile ducts were wide and well visible. In 120-day-old rabbits with a high level of *E. stiedae*, the gallbladder was enlarged 2–3 times due to excessive overflow of thick dark green bile (Fig. 3).

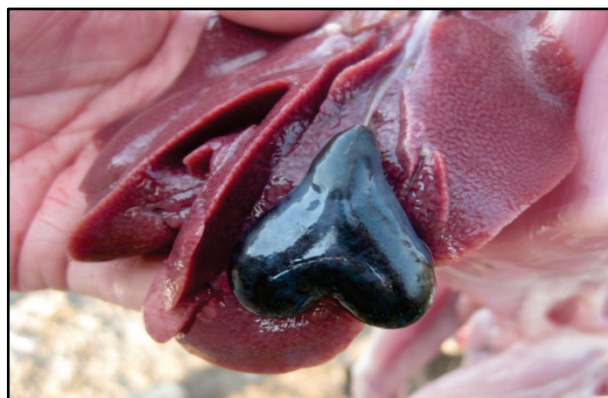


Fig. 3. Rabbit gallbladder is full of bile with a high level of *E. stiedae*

Instead, in 320-day-old rabbits with a low level of *E. stiedae*, we registered a reduction in the gallbladder (“devastated” gallbladder). The bladder was reduced by 1.5–2.0 times in size and outwardly had the appearance of a “grey” strand (Fig. 4). A moderately narrow course, a slight thickening of its wall and a brownish-greenish content resembling mucus were recorded in the section of the organ. The folds of the mucous membrane were moderately thickened.

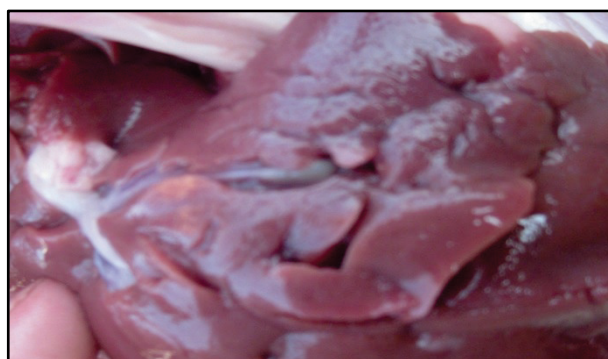

Fig. 4. Visual absence of the gallbladder in rabbits-parasitic carriers on low level of *E. stiedae*

The total infestation of 60-day-old rabbits with helminths was 22.2%, 120-day-old rabbits – 26.7%, and 180- and 320-day-old rabbits – 20.0% and 20.6%, respectively (Table 2). Infections of *T. pisiformis* in 9.4% of rabbits and *P. ambiguus* in 6.7% of animals were the most common in young animals aged 60 days. There was a significantly lower percentage of rabbits affected by other species of helminths – *T. retortaeformis* and *N. leporis* – 3.9% and 2.2%, respectively.

Table 2

Distribution of helminths in rabbits of different age groups ($\bar{x} \pm SE$, n = 180)

Pathogen	60 days of age		120 days of age		180 days of age		320 days of age	
	infected/ prevalence, %	intensity, spe- cimens/ animal	infected/ prevalence, %	intensity, spe- cimens/ animal	infected/ prevalence, %	intensity, spe- cimens/ animal	infected/ prevalence, %	intensity, spe- cimens/ animal
<i>Trichostrongylus retortaeformis</i> (Zeder, 1800)	7/3.9	26.52 ± 2.34	8/4.4	49.12 ± 3.13	4/2.2	86.71 ± 3.69	6/3.3	187.41 ± 3.42
<i>Nematodirus leporis</i> (Ransom, 1907)	4/2.2	8.26 ± 1.23	5/2.8	13.65 ± 2.36	5/2.8	17.45 ± 2.01	5/2.8	29.85 ± 1.12
<i>Passalurus ambiguus</i> (Rudolphi, 1819)	12/6.7	21.42 ± 1.01	13/7.2	43.83 ± 2.14	13/7.2	116.25 ± 2.39	12/6.7	72.45 ± 0.29
<i>Taenia pisiformis</i> (Bloch, 1780)	17/9.4	23.62 ± 0.53	22/12.2	49.52 ± 2.59	14/7.8	67.14 ± 2.22	14/7.8	73.51 ± 3.17

In 180-day-old rabbits, the extent of pathogen damage was the lowest, but the intensity of the invasion increased. Due to reinvasion, the intensity of *P. ambiguus* increased 4.0 times, *T. retortaeformis* increased 3.3 times and *T. pisiformis* increased 2.8 times compared to 60-day-old rabbits. During the dissection of rabbits, small spindle-shaped white helminths *P. ambiguus* were found in the cavity of the colon. The intensity was high and was 167.24 ± 2.47 specimens/animal (Fig. 5). Also in rabbits of this age group a high degree of intensity of *T. pisiformis* was regis-

tered – 67.14 ± 2.22 cysticerci. The largest number of cysticercosis vesicles was on the mesentery and omentum, and at low intensity of cysticercosis invasion, the vesicles were localized only on the serous membrane of the rectum (Fig. 6). In 320 day-old rabbits, along with live cysticerci, the presence of degenerated *T. pisiformis* as a result of different life expectancy of parasites and re-infection of animals was recorded. It should be noted that 42% of cysticerci were dark brown, i.e. degenerate, which indicated their non-viability (Fig. 7).

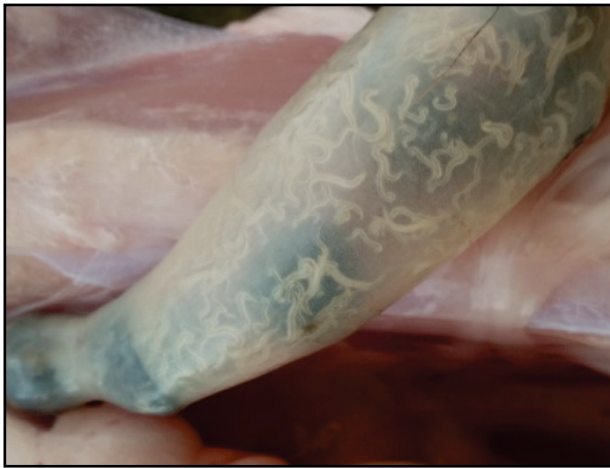

Fig. 5. *Passalurus ambiguus* in the cavity of the colon

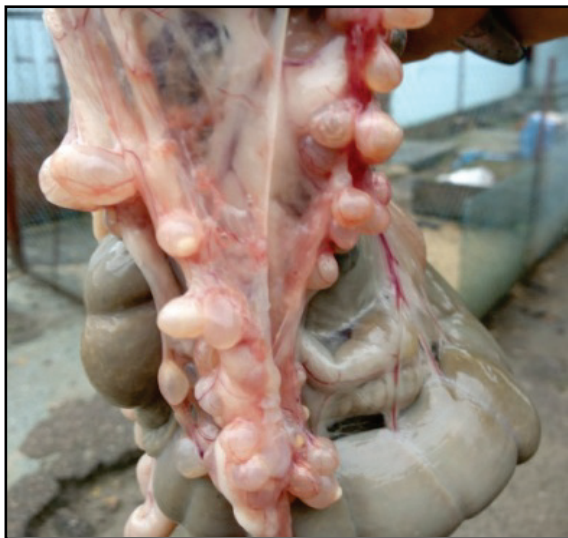

Fig. 6. *Taenia pisiformis* on the mesentery

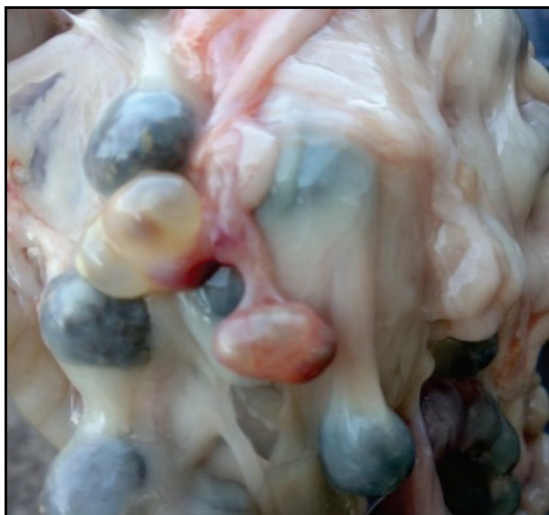

Fig. 7. Degenerated *Taenia pisiformis* on the mesentery

Adult rabbits also showed a 7.1-fold increase in the intensity of *T. retortaeformis* lesions, leading to intestinal enlargement and bloating (Fig. 8).

Discussion

Parasitism is one of the antagonistic trophic relations in which an organism uses another species (host) as a temporary or constant place for

living and source of nutrients. It completely depends on the host, negatively affects the host's condition, and can cause the host's death (Boyko et al., 2016). According to numerous studies, parasitoses contribute to development of somatic diseases, complications of chronic diseases, and affect the immune system. Characteristic of most helminths is the chronic course of the disease, related to the long term presence of the pathogen in the organism and possibility of repeating the infestation (Kirillova et al., 2020, 2021). At the same time, clinical features are manifested poorly, and pathological-anatomical changes are accompanied by productive processes which can practically change the functioning of part of the organ. A significant role in the pathogenesis of helminthoses is considered to be played by their mechanical impact conditioned by fixation of the parasites (using suckers, spikes, mouth capsules, cutting plates) and traumatization of the tissues or the host's organ, and is also related to the migration of larvae in the organism. During migration, nematode larvae synthesize enzymes which activate their penetration to their places of localisation. At the same time, helminth larvae provide opportunities for penetration of infectious agents (Thompson et al., 1994).

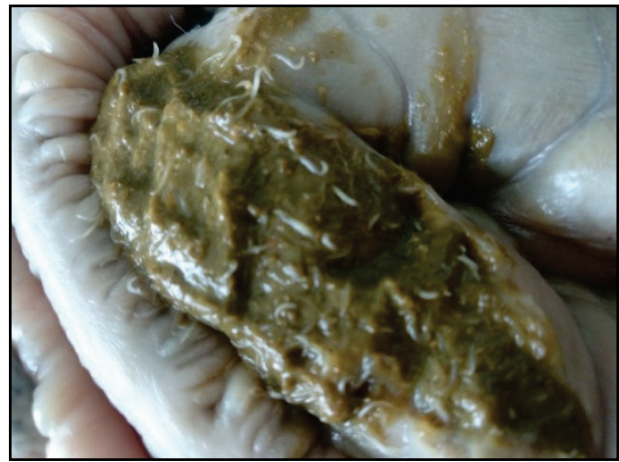

Fig. 8. *Trichostrongylus retortaeformis* in the chyme of the intestinal mass

Researchers believe that intestinal parasitosis is primarily a sanitary problem, and its prevention should be based on constant sanitary and parasitological monitoring (Atehmengo & Nnagbo, 2014; Takeuchi-Storm et al., 2019). One of the conditions that can cause susceptibility of the host organism and transmission of parasites is the occurrence of concomitant infections. Parasites persist directly inside the body and often these interactions modulate the host's immune response (Cattadori et al., 2007; Foster & Elsheikha, 2012).

Domestic rabbits belonging to the species *Oryctolagus cuniculus* are social animals and are descended from European animals (Owuor et al., 2019). It is well known that domestic rabbits are intended for meat consumption and are a valuable source of a number of nutrients, but may contain many different endoparasites, including *Passalurus ambiguus* (Abdel-Gaber et al., 2019), *Trichostrongylus retortaeformis* (Cattadori et al., 2019), *Nematodirus leporis* (Tizzani et al., 2020), *Cysticercus pisiformis* (Chen et al., 2021) and *Eimeria* spp. (Ladron de Guevara et al., 2019).

Gastrointestinal disorders in rabbits with coccidiosis are characterized by diarrhea, which can lead to high mortality (Shola et al., 2019). At the same time, intensive rabbit breeding has led to an increase in the transmission of parasites with a direct life cycle (*P. ambiguus* and *Eimeria* spp.) (Rinaldi et al., 2007; Kornaś et al., 2015). *Passalurus ambiguus* and *Eimeria* spp. are two common intestinal parasites in rabbits that can, among other symptoms, cause diarrhea and, in severe cases, death (Sioutas et al., 2021).

Parasitological examination of the internal organs of domestic rabbits revealed damage by coccidia (78.8%), nematodes (*Obeliscooides cuniculi*, *Graphidium strigosum*, *Trichostrongylus* spp., *Strongyloides* spp., *Passalurus ambiguus*, *Trichuris leporis*) (16.4%) and cestodes *Cysticercus pisiformis* (4.7%). The intestinal form of coccidiosis was dominant and reached 56.5%, while the extensiveness of the hepatic form of coccidiosis was significantly lower – 3.3% of the surveyed rabbits (Szkucik et al.,

2014). In Finnish domestic rabbits, *Eimeria* oocysts were detected in 27% of samples, *Passalurus ambiguus* eggs were detected in 3% of samples, and *Trichostrongylus leporis* eggs and cestode eggs, respectively, were detected in 1 sample (0.25%) (Mäkitaipale et al., 2017). Some studies show that the largest proportion of infected rabbits (95.8–100.0%) are animals from rabbit farms (Hamid et al., 2019; Sioutas et al., 2021). Excessive stocking density of animals with extensive housing system, contributes to the rapid spread of the invasion. Significantly lower prevalence of coccidiosis (8.3–51.0%) is recorded in rabbits living in the wild (Foronda et al., 2005; Silva et al., 2015). In the province of Grosseto (Central Italy), necroscopic analysis of wild hares revealed the helminths *Trichostrongylus retortaeformis* (87.1%), *Passalurus ambiguus* (12.9%), and *Andrya* spp. (6.4%) in the intestines, *Protostrongylus cuniculorum* (8.3%) in the lungs and *Dicrocoelium dendriticum* (16.7%) in the liver. The prevalent intestinal helminths in breeding hares were *Passalurus ambiguus* (12.1%) and *Trichostrongylus retortaeformis* (3%). Coprological analysis showed the prevalence of coccidia at the level of 64.9% in wild hares and 45.5% in bred hares (Sergi et al., 2018). Chylinski et al. (2009) note that the intensity of *Trichostrongylus retortaeformis* increased and reached a maximum in young rabbits and decreased slightly in adults. The causative agent of *Trichostrongylus retortaeformis* was the second most numerous species of nematode with an extent of 42% among various breeds of domestic rabbits, while in wild rabbits it had a prevalence of 11.6% (Yagoob & Hossein, 2011).

Mignati et al. (2016) note that global climate change will change the distribution and dynamics of soil-borne helminthiasis, but host immunity may also affect host-parasite interactions. Most of the problems that affect the physiological state of the domestic rabbit's gastrointestinal tract are caused by hereditary or housing factors, many of which can be addressed through basic veterinary procedures and proper diet (Harrenstien, 1999; Nowland et al., 2015). Thus, knowledge of the dependence of the extent and intensity of the invasion of diseases of the digestive organs of rabbits on their age and season is a well-founded indicator in the planning and implementation of treatment and prevention measures.

Conclusions

It has been proved that in the south of Ukraine, rabbit endoparasitoses are a fairly common invasive disease, the causative agents of which are *Trichostrongylus retortaeformis*, *Nematodirus leporis*, *Passalurus ambiguus*, *Taenia pisiformis* and *Eimeria stiedae*, *E. magna*. 60-day-old rabbits are most infected with the intestinal *Eimeria* - *E. magna* and *E. media*, 120-day-old rabbits are most infected with the hepatic form of eimeriosis caused by *E. stiedae*, while in adult rabbits eimeriosis is recorded as a carriers. *Trichostrongylus retortaeformis* and *Taenia pisiformis* were mostly recorded in 120-day-old rabbits, while the extensiveness of *Passalurus ambiguus* and *Nematodirus leporis* was almost the same in all age groups.

Authors state no conflict of interest.

References

Abdel-Gaber, R., Ataya, F., Fouad, D., Daoud, M., & Alzuhairy, S. (2019). Prevalence, morphological and molecular phylogenetic analyses of the rabbit Pinworm, *Passalurus ambiguus* Rudolphi 1819, in the domestic rabbits *Oryctolagus cuniculus*. *Acta Parasitologica*, 64(2), 316–330.

Ahmed, H., Naz, M., Mustafa, I., Khan, M. R., Asif, S., Afzal, M. S., Arshad, M., Naveed, M., Ali, S., & Simsek, S. (2017). Impact of epidemiological factors on the prevalence, intensity and distribution of ectoparasites in pigeons. *Journal of Parasitic Diseases*, 41(4), 1074–1081.

Athemengo, N. L., & Nnagbo, C. S. (2014). Emerging animal parasitic diseases: A global overview and appropriate strategies for their monitoring and surveillance in Nigeria. *The Open Microbiology Journal*, 8, 87–94.

Bochyńska, D., Lloyd, S., Restif, O., & Hughes, K. (2022). *Eimeria stiedae* causes most of the white-spotted liver lesions in wild European rabbits in Cambridge-shire, United Kingdom. *Journal Veterinary Diagnostics Invest*, 34(2), 199–205.

Bogach, M. V., Horobei, O. O., Ivanchenko, O. M., & Vovk, D. V. (2020). Monitoring of cysticercosis of rabbits in farms of different forms of ownership. *Journal for Veterinary Medicine, Biotechnology and Biosafety*, 6(3), 9–12.

Bowman, D. D. (2020). *Georgis: Parasitology for Veterinarians eBook*. Elsevier Health Sciences.

Boyko, O. O., & Brygadyrenko, V. V. (2019). The impact of acids approved for use in foods on the vitality of *Haemonchus contortus* and *Strongyloides papillosus* (Nematoda) larvae. *Helminthologia*, 56(3), 202–210.

Boyko, O. O., Zazharska, N. M., & Brygadyrenko, V. V. (2016). The influence of the extent of infestation by helminths upon changes in body weight of sheep in Ukraine. *Visnyk of Dnipropetrovsk University, Biology, Ecology*, 24(1), 3–7.

Boyko, O., Shendryk, L., Shaban, O., & Brygadyrenko, V. (2021). Influence of essential oils on sporulation of *Eimeria magna* oocysts. *Annals of Parasitology*, 67(1), 11–17.

Cattadori, I. M., Albert, R., & Boag, B. (2007). Variation in host susceptibility and infectiousness generated by co-infection: The myxoma-*Trichostrongylus retortaeformis* case in wild rabbits. *Journal of the Royal Society, Interface*, 4(16), 831–840.

Cattadori, I. M., Pathak, A. K., & Ferrari, M. J. (2019). External disturbances impact helminth-host interactions by affecting dynamics of infection, parasite traits, and host immune responses. *Ecology and Evolution*, 9(23), 13495–13505.

Chen, G., Wang, L., Liu, T., Li, Y., Zhang, S., Li, H., & Luo, X. (2021). Identification and expression profiling of circulating microRNAs in serum of *Cysticercus pisiformis*-infected rabbits. *Genes*, 12(10), 1591.

Chylinski, C., Boag, B., Stear, M. J., & Cattadori, I. M. (2009). Effects of host characteristics and parasite intensity on growth and fecundity of *Trichostrongylus retortaeformis* infections in rabbits. *Parasitology*, 136(1), 117–123.

Dolbin, D. A., Tiurin, I. A., & Khairullin, R. M. (2012). Algorithm for the coproscopic diagnosis of human intestinal parasites. *Medical Parasitology and Parasitic Diseases*, 2, 30–32.

Duda, Y. V., Prus, M. P., Kuneva, L. V., & Shevchuk, R. S. (2018). Influence of cysticercosis invasion on the condition of internal organs and meat productivity of rabbits. *Veterinary Biotechnology*, 33, 31–38.

Foronda, P. R., Figueruelo, E. O., Ortega, A. R., Abreu, N. A., & Casanova, J. C. (2005). Parasites (viruses, coccidia and helminths) of the wild rabbit (*Oryctolagus cuniculus*) introduced to Canary Islands from Iberian Peninsula. *Acta Parasitologica*, 50(1), 80–84.

Foster, N., & Elsheikha, H. M. (2012). The immune response to parasitic helminths of veterinary importance and its potential manipulation for future vaccine control strategies. *Parasitology Research*, 110(5), 1587–1599.

Hajipour, N., & Zavarshani, M. (2020). Ectoparasites and endoparasites of New Zealand white rabbits from North West of Iran. *Iranian Journal of Parasitology*, 15(2), 266–271.

Hamid, P. H., Prastowo, S., & Kristianingrum, Y. P. (2019). Intestinal and hepatic coccidiosis among rabbits in Yogyakarta, Indonesia. *Veterinary World Journal*, 12(8), 1256–1260.

Harrenstien, L. (1999). Gastrointestinal diseases of pet rabbits. *Seminars in Avian and Exotic Pet Medicine*, 8(2), 83–89.

Hernandez, A. D., Boag, B., Neilson, R., & Forrester, N. L. (2018). Variable changes in nematode infection prevalence and intensity after Rabbit Haemorrhagic Disease Virus emerged in wild rabbits in Scotland and New Zealand. *International Journal for Parasitology, Parasites and Wildlife*, 7(2), 187–195.

Hrzerjak, N. M., Zadravec, M., Švara, T., & Račnik, J. (2021). Hepatic coccidiosis in two pet rabbits. *Journal of Exotic Pet Medicine*, 36, 53–56.

Jiménez, B., Maya, C., Velásquez, G., Tomer, F., Arambula, F., Barrios, J. A., & Velasco, M. (2016). Identification and quantification of pathogenic helminth eggs using a digital image system. *Experimental Parasitology*, 166, 164–172.

Kabene, S., & Baadel, S. (2019). Bioethics: A look at animal testing in medicine and cosmetics in the UK. *Journal of Medical Ethics and History of Medicine*, 12, 12–15.

Kirillova, N. Y., Kirillov, A. A., & Ruchin, A. B. (2021). First record of helminths of the European pine vole, *Microtus subterraneus* (Rodentia, Cricetidae) in Russia with overview on the rodent's range. *Russian Journal of Theriology*, 20(1), 19–24.

Kirillova, N. Y., Kirillov, A. A., Ruchin, A. B., & Trukhachev, M. V. (2020). Helminth fauna of *Microtus cf. arvalis* (Rodentia, Cricetidae) in Russia and adjacent countries. *Biodiversitas*, 21, 1961–1979.

Knopp, S., Glinz, D., Rinaldi, L., Mohammed, K. A., N'Goran, E. K., Stothard, J. R., Marti, H., Cringoli, G., Rollinson, D., & Utzinger, J. (2009). FLOTAC: A promising technique for detecting helminth eggs in human faeces. *Transactions of the Royal Society of Tropical Medicine and Hygiene*, 103(12), 1190–1194.

Komaš, S., Kowal, J., Wierzbowska, I., Basiaga, M., Nosal, P., & Niedbala, P. (2015). The Alice – “Follow the White Rabbit” – parasites of farm rabbits based on coproscopy. *Annals of Parasitology*, 61(4), 257–261.

Laakkonen, J., Nyyssönen, T., Hiltunen, M., Kauhala, K., Nikander, S., & Soveri, T. (2006). Effects of *Protostrongylus* sp. and *Pneumocystis* sp. on the pulmonary tissue and the condition of mountain and brown hares from Finland. *Journal of Wildlife Diseases*, 42(4), 780–787.

Ladron de Guevara, O. S., Perez-Rivero, J. J., Perez-Martinez, M., Flores-Perez, F. I., & Romero-Callejas, E. (2019). *Eimeria* spp. in broiler rabbit: Seasonal prevalence in the backyard farms of the State of Mexico. *Veterinaria Italiana*, 55(2), 183–187.

Lans, C., & Tumer, N. (2011). Organic parasite control for poultry and rabbits in British Columbia, Canada. *Journal of Ethnobiology and Ethnomedicine*, 7, 21.

- Li-Qun, W., Ting-Li, L., Pan-Hong, L., Shao-Hua, Z., Tao-Shan, L., Yan-Ping, L., Guang-Xue, L., Li, M., & Xue-Nong, L. (2020). Characterization of exosome-like vesicles derived from *Taenia pisiformis* cysticercus and their immunoregulatory role on macrophages. *Parasit and Vectors*, 13(1), 318–334.
- Mäkitaipale, J., Karvinen, I., Virtala, A. K., & Näreaho, A. (2017). Prevalence of intestinal parasites and risk factor analysis for *Eimeria* infections in Finnish pet rabbits. *Veterinary Parasitology, Regional Studies and Reports*, 9, 34–40.
- Mignatti, A., Boag, B., & Cattadori, I. M. (2016). Host immunity shapes the impact of climate changes on the dynamics of parasite infections. *Proceedings of the National Academy of Sciences of the United States of America*, 113(11), 2970–2975.
- Nakao, M., Sasaki, M., Waki, T., Iwaki, T., Morii, Y., Yanagida, K., Watanabe, M., Tsuchitani, Y., Saito, T., & Asakawa, M. (2019). Distribution records of three species of *Leucochloridium* (Trematoda: Leucochloridiidae) in Japan, with comments on their microtaxonomy and ecology. *Parasitology International*, 72, 101936.
- Nasser, H., & Zavarshani, M. (2020). Ectoparasites and endoparasites of New Zealand White Rabbits from North West of Iran. *Iran Journal Parasitology*, 15(2), 266–271.
- Nowland, M. H., Brammer, D. W., Garcia, A., & Rush, H. G. (2015). Biology and diseases of rabbits. In: Fox, J. G., Anderson, L. C., Otto, G. M., Pritchett-Coming, & Whary, M. T. (Eds.). *Laboratory Animal Medicine*. Academic Press. Pp. 411–461.
- Ola-Fadunsin, S. D., Hussain, K., Rabi, M., & Ganiyu, I. A. (2018). Parasitic conditions of domestic owned rabbits in Osun State, Southwestern Nigeria: Retrospective evaluation, risk factors and co-infestations. *International Journal of Veterinary Science and Medicine*, 6(2), 208–212.
- Owuor, S. A., Mamati, E. G., & Kasili, R. W. (2019). Origin, genetic diversity, and population structure of rabbits (*Oryctolagus cuniculus*) in Kenya. *BioMed Research International*, 2019, 7056940.
- Pilarczyk, B., Tomza-Marciniak, A., Pilarczyk, R., Janus, E., Stanek, P., Seremak, B., & Sablik, P. (2020). The effect of the sex, age, and breed of farmed rabbits and the choice of management system on the extensity and intensity of *Eimeria* infection. *Veterinary World*, 13(8), 1654–1660.
- Rinaldi, L., Russo, T., Schioppi, M., Pennacchio, S., & Cringoli, G. (2007). *Passalurus ambiguus*: New insights into copromicroscopic diagnosis and circadian rhythm of egg excretion. *Parasitology Research*, 101(3), 557–561.
- Sergi, V., Romeo, G., Serafini, M., Torretta, E., & Macchioni, F. (2018). Endoparasites of the European hare (*Lepus europaeus* (Pallas, 1778)) in Central Italy. *Helminthologia*, 55(2), 127–133.
- Sharma, R., Kapoor, D., & Kumar, R. (2017). A rare case of verminous pneumonia in domestic rabbit. *Journal of Parasitic Diseases*, 41(3), 716–717.
- Shola, D. O.-F., Nuhu, A. A., Fabiyi, J. P., Sanda, I. M., Hussain, K., Rabi, M., Isau, A., & Ganiyu, I. A. (2019). Prevalence and associated risk factors of *Eimeria* species in rabbits (*Oryctolagus cuniculus*) in Ilorin, Kwara State, Nigeria. *Annals of Parasitology*, 65(3), 267–273.
- Silva, S. M., Ferreira, C., Paupério, J., Silva, R. M., Alves, P. C., & Lemos, A. (2015). Coccidiosis in European rabbit (*Oryctolagus cuniculus algirus*) populations in the Iberian Peninsula. *Acta Parasitologica*, 60(2), 350–355.
- Simmonds, R. C. (2017). Chapter 4. Bioethics and animal use in programs of research, teaching, and testing. In: Weichbrod, R. H., Thompson, G. A. H., & Norton, J. N. (Eds.). *Management of animal care and use programs in research, education, and testing*. CRC Press, Taylor & Francis, Boca Raton. Pp. 1–28.
- Sioutas, G., Evangelou, K., Vlachavas, A., & Papadopoulos, E. (2021). Deaths due to mixed infections with *Passalurus ambiguus*, *Eimeria* spp. and *Cyniclomyces guttulatus* in an industrial rabbit farm in Greece. *Pathogens*, 10(6), 756.
- Soulsby, E. J. L. (1982). *Helminths, arthropods and protozoa of domestic animals*. (7th edition). Baillière Tindall, London.
- Szkucik, K., Pyz-Lukasik, R., Szczepaniak, K. O., & Paszkiewicz, W. (2014). Occurrence of gastrointestinal parasites in slaughter rabbits. *Parasitology Research*, 113(1), 59–64.
- Takeuchi-Storm, N., Moakes, S., Thüer, S., Grovermann, C., Verwer, C., Verkaik, J., Knubben-Schweizer, G., Höglund, J., Petkevicius, S., Thamsborg, S., & Weme, S. (2019). Parasite control in organic cattle farming: Management and farmers' perspectives from six European countries. *Veterinary Parasitology, Regional Studies and Reports*, 18, 100329.
- Thompson, S. N., & Kavaliers, M. (1994). Physiological bases for parasite-induced alterations of host behaviour. *Parasitology*, 109(S1), 119–138.
- Tizzani, P., Andrade, D., Min, A., Peano, A., & Meneguz, P. G. (2020). Does the introduction of alien species represent a sanitary threat for native species? The case of the eastern cottontail *Sylvilagus floridanus* in Italy. *Life*, 10(8), 142.
- Vaumourin, E., Vourch, G., Gasqui, P., & Vayssier-Taussat, M. (2015). The importance of multiparasitism: Examining the consequences of co-infections for human and animal health. *Parasites and Vectors*, 8, 545.
- Yagoob, G., & Hossein, H. (2011). Prevalence rate of endoparasites in wild rabbits of East-Azerbaijan Province, Iran. *Annals of Biological Research*, 2(6), 31–35.